

2026 Charleston APRN Conference

# Dermatology for Primary Care:

Diagnosis and Treatment of Cutaneous Disorders in 2026




PRESENTED BY:  
Michael Overcash PA




1

---

---

---

---

---

---

---


---

---

---

**Agenda:** What we'll cover today (based on your feedback!)

- Why dermatology matters in primary care
- Diagnostic approach: history, exam, distribution, tools
- Updates : what to know about JAK inhibitors etc.
- Dermatologic Misconceptions
- Key takeaways



2

---

---

---

---

---

---

---

---


---

---

# The Importance of Dermatology in Primary Care

**Why Dermatology Matters in Primary Care:**

- Skin concerns account for about one-third of primary care visits.
- Many common rashes are manageable in primary care with clear algorithms.
- Early recognition reduces morbidity and avoids unnecessary antibiotics/steroids.



3

---

---

---

---

---

---

---

---

---

---

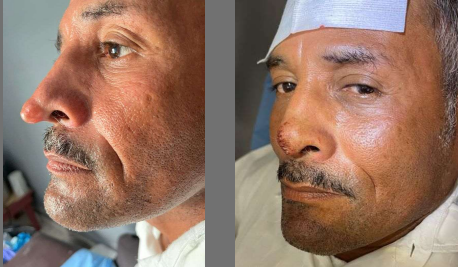





## Be Systematic:

- A useful template for describing lesions is as follows:
- On the [location] are [symptom, color, texture, configuration] of [primary lesion].



13

---

---

---

---

---

---

---

---

## Systematic examples:

- On the **location** are **symptom, color, texture, configuration** of **primary lesion**.

"On the left trunk there are painful red raised vesicles in a dermatomal pattern"

What is being described?



14

---

---

---

---

---

---

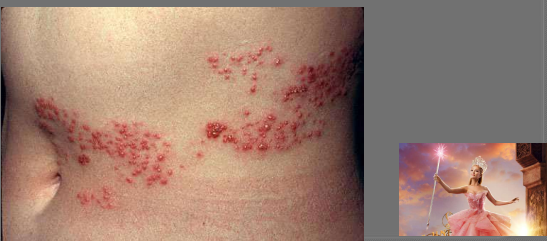---

---

## Systematic examples:

- On the **location** are **symptom, color, texture, configuration** of **primary lesion**.

"On the left trunk there are painful red raised vesicles in a dermatomal pattern" = **SHINGLES !**



15

---

---

---

---

---


---

---

---

**Systematic examples:**

- ⦿ OK NOW PRACTICE :  
on the **location** are **symptom, color, texture, configuration** of **primary lesion**.



16

---

---

---

---

---

---


---

---

**Systematic examples:**

- ⦿ On the **location** are **symptom, color, texture, configuration** of **primary lesion**.

"On extensor elbows there are asymptomatic pink scaly well defined plaques"



[Psoriasis]

17

---

---

---

---

---


---

---

---

**Systematic examples:**

- ⦿ PRACTICE ONE MORE:  
On the **location** are **symptom, color, texture, configuration** of **primary lesion**.



18

---

---

---

---

---

---

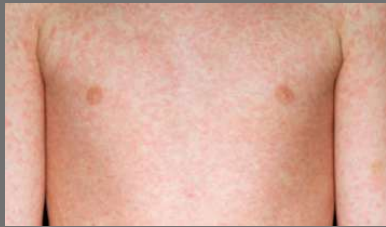---

---

### Systematic examples:

- On the **location** are **symptom, color, texture, configuration** of **primary lesion**.

"Generalized itchy pink smooth lacy morbilliform eruption of confluent macules"



[viral exanthem]

19

---

---

---

---

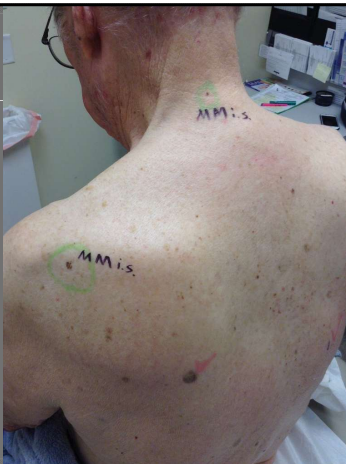---

---

---

---

- The worst exam, is the one that never happened
- Goals: Less makeup, less clothing, better lighting, and a trained eye



20

---

---

---

---

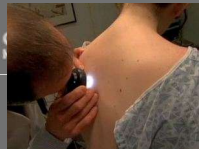---

---

---

---

- Take a good History and Physical
- Exam should be in a well-lit room
- Use a bright white **penlight**
- Attempt to identify the **primary lesion(s)**.
- photograph if possible
- Don't forget to examine **nails**, hair and mucosa
- When necessary, check for adenopathy, tenderness, compressibility, edema, blanching
- Use a loupe, magnifier, or **dermatoscope**
- Consider physical maneuvers (e.g., rubbing the skin to elicit dermatographism)
- have the patient disrobed and draped, examine whole areas in segments



21

---

---

---


---

---

---

---

---

Approach to diagnosis for a given presentation 

- Describing the lesion or eruption will put it in a category
- Use that category to build a differential
- Explore the list and rule out DDx until the final Dx is known
- Use colleagues and online sources or textbooks: Medscape, UpToDate, VisualDx, dermnet.nz, Doximity AI;
- DRAG AND DROP ENTIRE CHART NOTES INTO MEDICAL A.I. -> OpenEvidence !

**OpenEvidence**®

22

---

---

---

---

---

---

---

---

**You don't want to miss....**



Because you didn't look!  
The worst exam is the one that never happened.

23

---

---

---


---

---

---

---

---



Malignant melanoma in 27-year-old

24

---

---

---

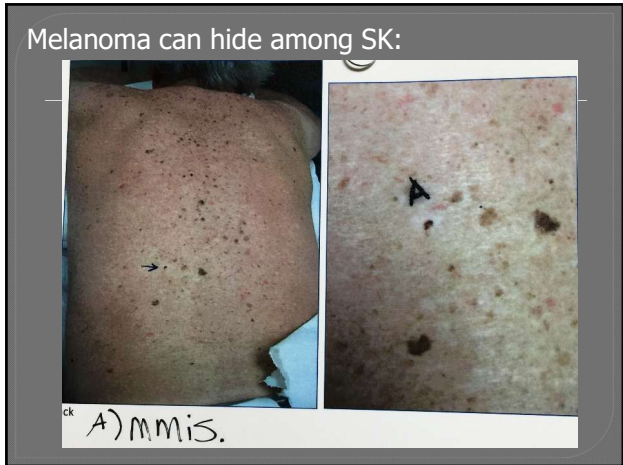---

---

---

---

---



25

---

---

---

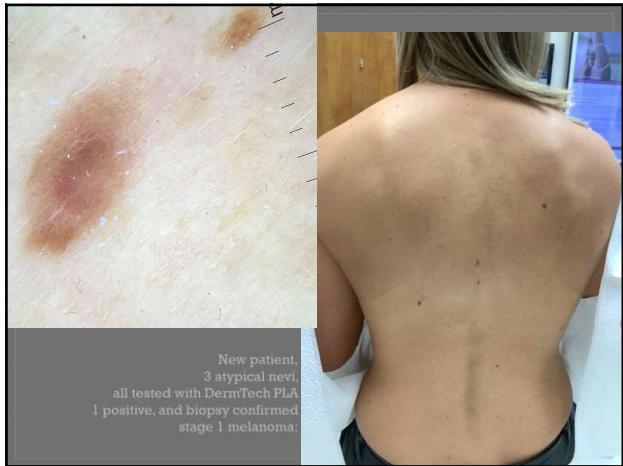---

---

---

---

---



26

---

---

---

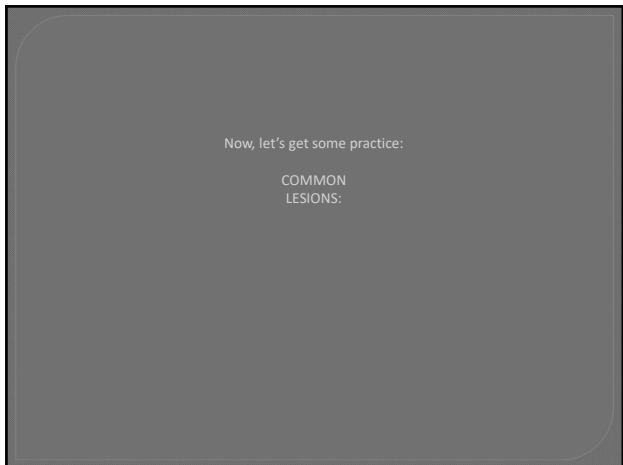
---

---

---

---

---



27

---

---

---

---

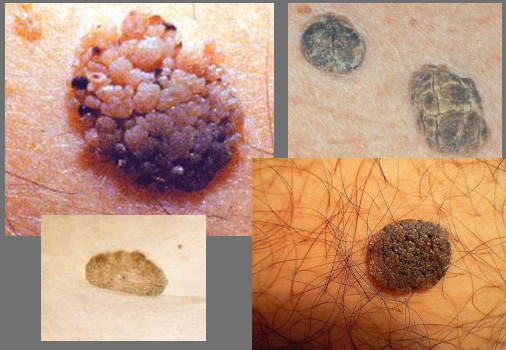---

---

---

---

### Seborrheic Keratosis



28

---

---

---

---

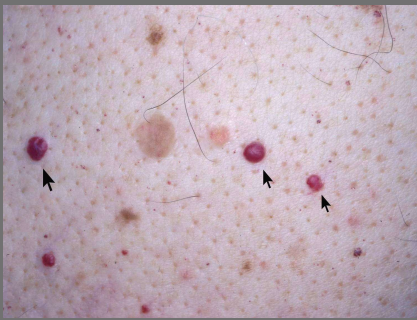---

---

---

---

### Cherry Angiomas



29

---

---

---

---

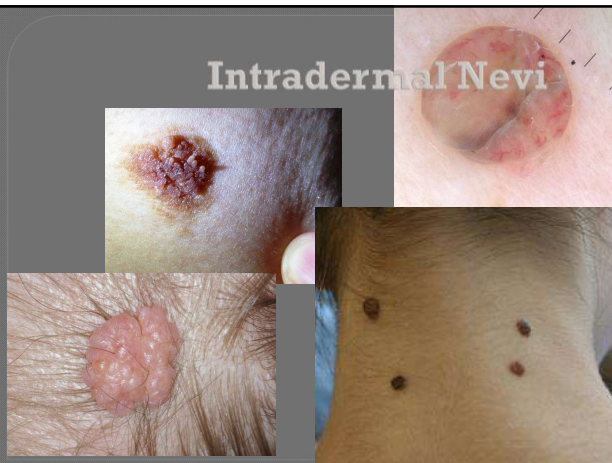---

---

---

---

### Intradermal Nevi



30

---

---

---

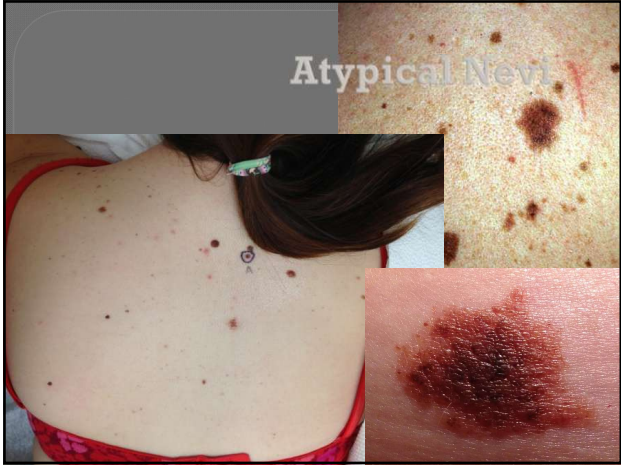---

---

---

---

---



31

---

---

---

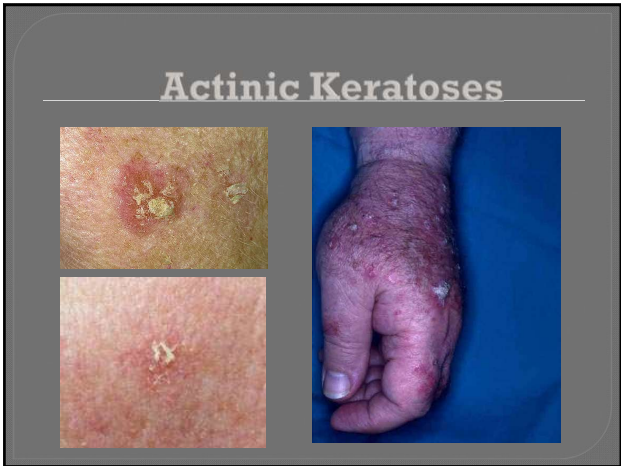---

---

---

---

---



32

---

---

---

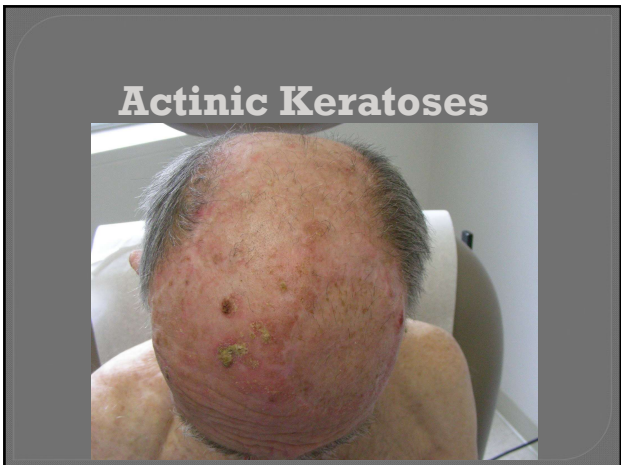---

---

---

---

---



33

---

---

---

---

---

---

---

---

### ACTINIC KERATOSIS - treatment

- ◉ Related to cumulative sun exposure
- ◉ 1-5% progress to malignancy
- ◉ Evolves from thin AK to hypertrophic AK to SCC
- ◉ Tx :
  - Topical therapy:
    - 5-florouracil
    - Imiquimod
    - ingenol mebutate
  - photodynamic therapy
  - Destruction (cryosurgery most common)



34

---

---

---

---

---

---

---

---

### Basal Cell Carcinoma



35

---

---

---

---

---

---

---

---

### Basal Cell Carcinoma



36

---

---

---

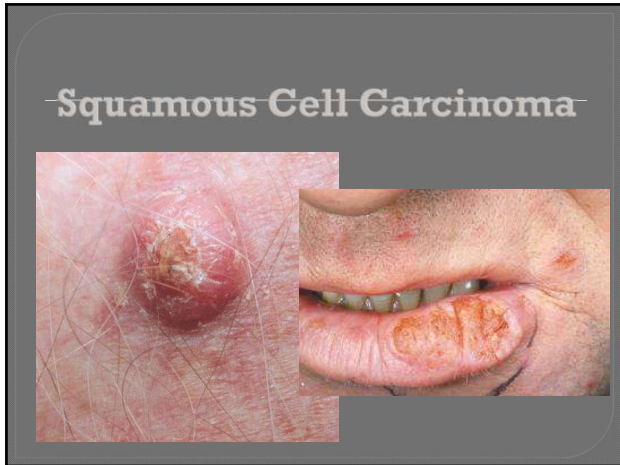---

---

---

---

---



37

---

---

---

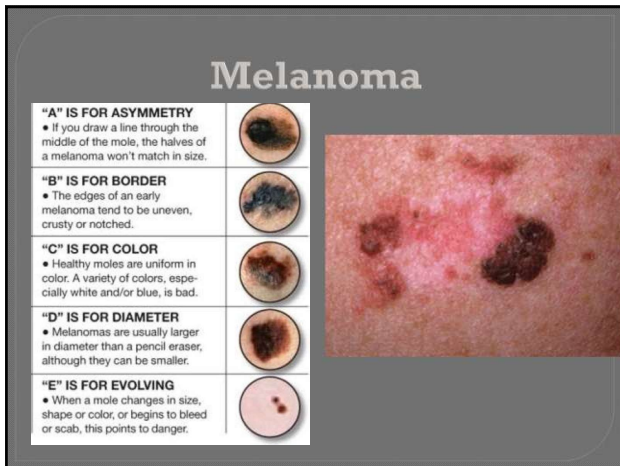
---

---

---

---

---



38

---

---

---

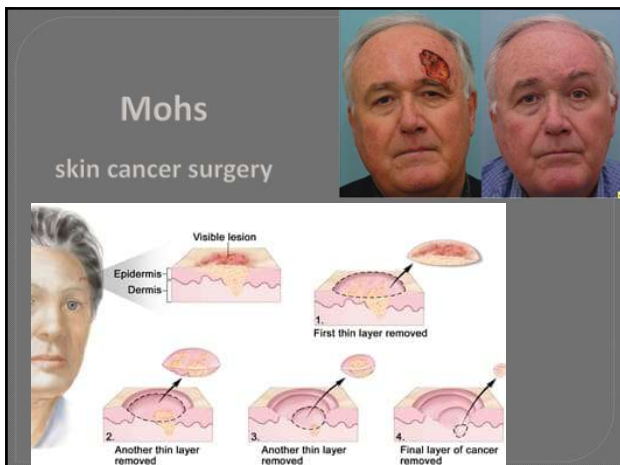
---

---

---

---

---



39

---

---

---

---

---

---

---

---

# Recognition and Treatment of selected skin disorders

40

---

---

---

---

---

---

---

---

Cystic acne

Leads to depression rates on par with cancer dx.  
Increased<sup>1,2</sup>:

- suicide
- incarceration
- dropout rate
- low income

<sup>1</sup>Barnes, L.F., Levander, M.M., Fleischer, A.B., 3<sup>rd</sup>, Feldman, S.R. (April 2012). "Quality of life measures for acne patients". *Dermatologic Clinics (Review)* 30 (2): 297-300. <https://doi.org/10.1016/j.det.2011.11.016>  
<sup>2</sup>Scotton, G. (July 2002). <https://doi.org/10.1007/s10227-002-0001-0> *Acne and mental health: implications for the Australian family physician (Review)* 25 (7): 537-4. <https://doi.org/10.1007/s10227-002-0001-0>



41

---

---

---

---

---

---


---

---

Isotretinoin

a miracle cure for over 10,000,000 users!

70% are cured for life with one 6-month course



42

---

---

---

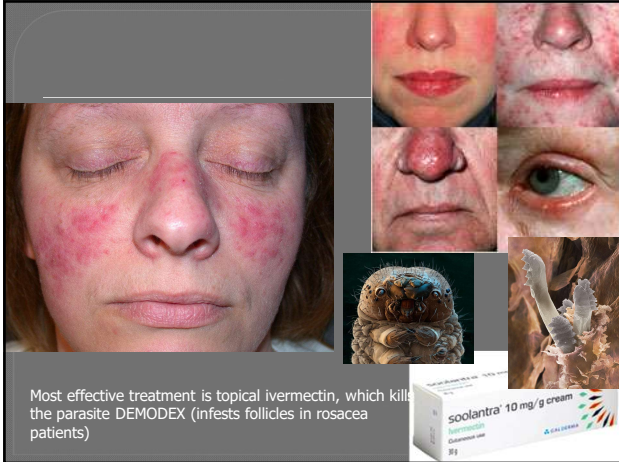---

---

---

---

---



43

---

---

---

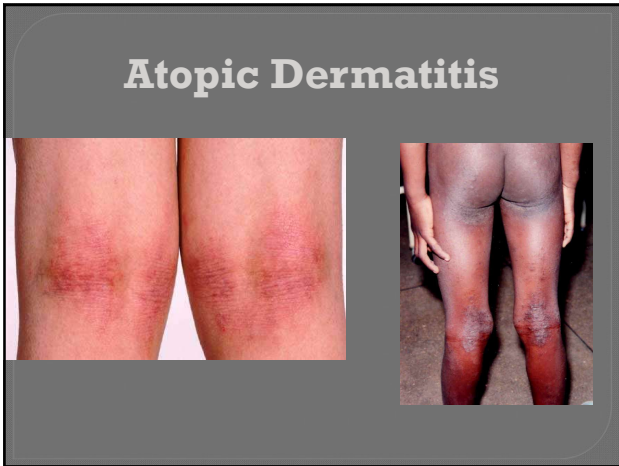
---

---

---

---

---



44

---

---

---

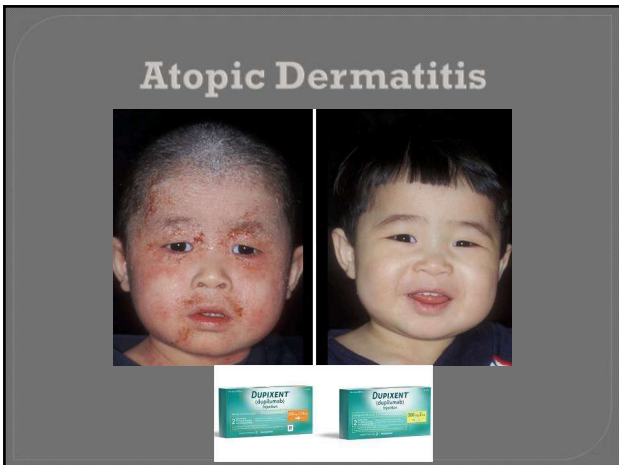
---

---

---

---

---



45

---

---

---

---

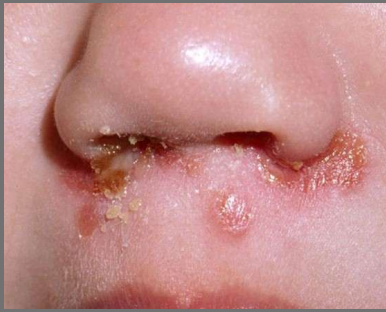---

---

---

---

### Impetigo



46

---

---

---

---

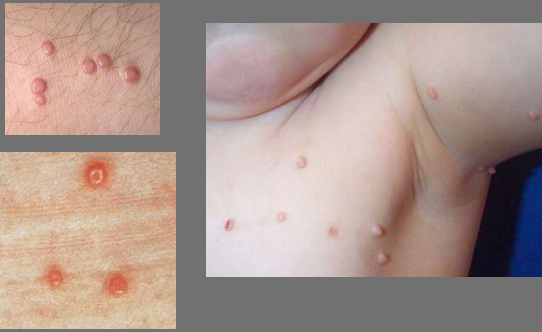---

---

---

---

### Molluscum Contagiosum



47

---

---

---

---

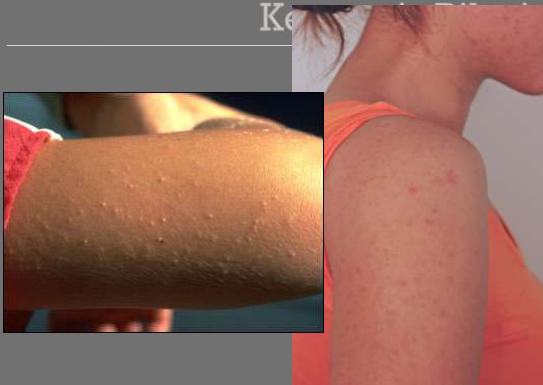---

---

---

---

### Ke



48

---

---

---

---

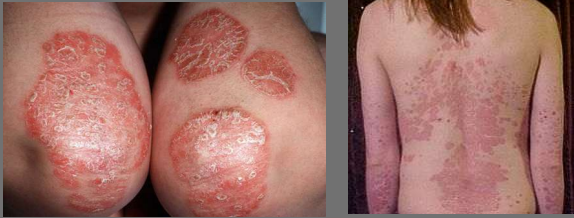---

---

---

---

## Psoriasis



49

---

---

---

---

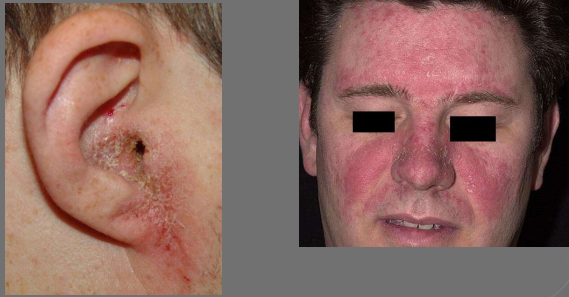---

---

---

---

## Seborrheic dermatitis



50

---

---

---

---

---

---

---

---

### REMINDER:

Approach to diagnosis for a given presentation



- ◉ Describing the lesion or eruption will put it in a category
- ◉ Use that category to build a differential
- ◉ Explore the list and rule out Ddx until the final Dx is known
- ◉ Use colleagues and online sources or textbooks: Medscape, UpToDate, VisualDx, dermnet.nz, Doximity AI;
- ◉ DRAG AND DROP ENTIRE CHART NOTES INTO MEDICAL A.I. -> OpenEvidence !

OpenEvidence®

51

---

---

---

---

---

---

---

---

### Needs Expedited Referral to Dermatology

- melanoma
- Erythroderma
- Psoriasis: if pustular and widespread : Never prednisone!
- Bullous/blistering disease
- Severe Drug reactions
- Ocular and oral disease



52

---

---

---

---

---

---

---

---

### First, a few MYTHS:



“15 minutes a day of sunlight is a good source of vitamin D”

53

---

---

---

---

---

---

---

---

### The TRUTH:

Sunlight is NOT a reliable source of vitamin D:

1. Vitamin D is LESS bioavailable from the sun, versus OTC supplements<sup>1</sup>
2. Sunlight is good for mental health, but irreversibly damages our skin
3. There are too many variables to rely on sunlight for vitamin D :
  - Skin color affects absorption
  - Location on the earth, time of day, weather
  - Area of exposed skin, and use of sunscreen



<sup>1</sup>Effect of sun exposure versus oral vitamin D supplementation on serum 25-hydroxyvitamin D concentrations in young adults: A randomized clinical trial. <https://doi.org/10.1038/s41591-018-03381>

54

---

---

---

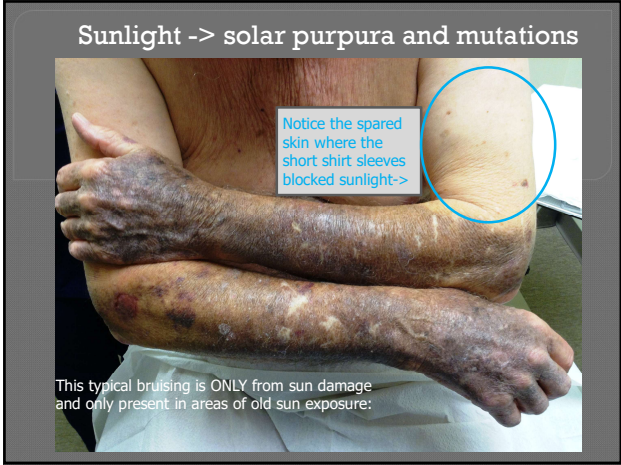
---

---

---

---

---



55

---

---

---

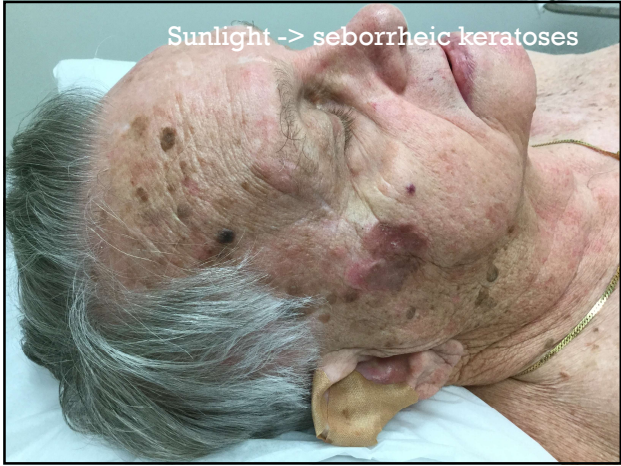---

---

---

---

---



56

---

---

---

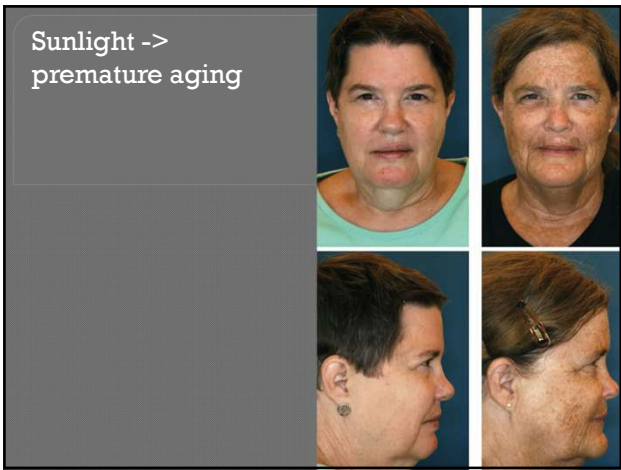
---

---

---

---

---



57

---

---

---

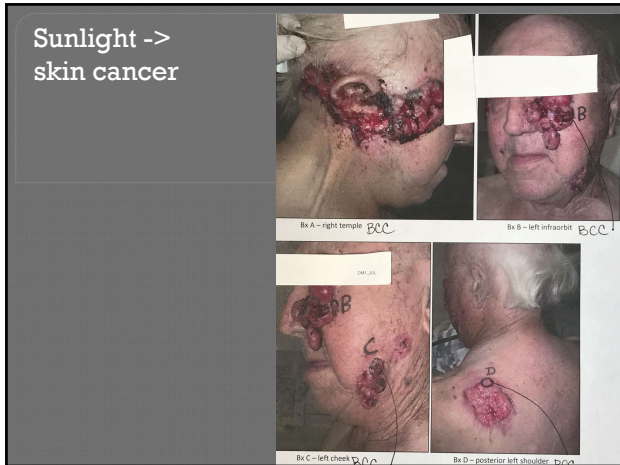---

---

---

---

---



58

---

---

---

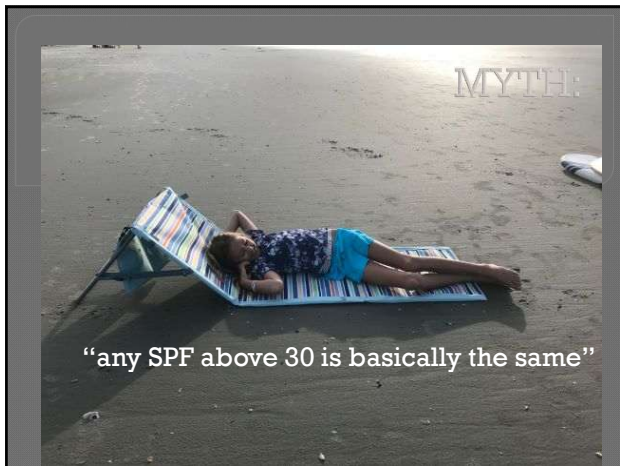---

---

---

---

---



59

---

---

---

---

---

---

---

---

TRUTH:

- SPF ratings are earned; higher SPFs protect better and longer<sup>1</sup>
- Spray sunscreens may damage lung tissue<sup>2</sup>
- Sunscreen ingredients are absorbed into the blood stream above FDA thresholds<sup>3</sup>

<sup>1</sup>SPF 100+ sunscreen is more protective against sunburn than SPF 50+ in actual use: Results of a randomized, double-blind, split-face, natural sunlight exposure clinical trial. 2017.12.052; Journal American Academy of Dermatology

<sup>2</sup>Arch Toxicol. 2014 Jan;88(1):65-75. Inhaled fine, oxide particles do not promote DHPN-induced lung carcinogenesis but cause reversible epithelial hyperplasia of terminal bronchioles

<sup>3</sup>JAMA. 2020 Jan 21;323(3):256-267. Effect of Sunscreen Application on Plasma Concentration of Sunscreen Active Ingredients: A Randomized Clinical Trial

WHAT WE WISH YOU KNEW... TRUTH... 2021

60

---

---

---

---

---

---

---

---



**MYTH:**

“molluscum contagiosum is benign and just goes away without treatment”

61

---

---

---


---

---

---



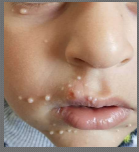
---

---



**TRUTH:**

- Pediatricians prefer not to treat molluscum, but prolonged infections lead to significant frustration for parents and children.
- Severe infections can lead to physical and emotional scarring, activity exclusion, pain and pruritus, and secondary infection
- It is safe and easy to treat MC with cantharidin (blister beetle juice)

62

---

---

---

---

---

---

---

---

**A new option for molluscum:**

- FDA recently approved some new formulations of Cantharone for application to Molluscum:
- Verrica and Ycanth : both aid precision application, great for first-time users:




**VERRICA PHARMACEUTICALS**  
Redefining Skin Science

**VP-102**

GMP-controlled formulation of cantharidin with:  
 • All-time highest purity (99.99%)  
 • Defined pharmaceutical batch process

Long-term, 100% temperature stability

Visualization agent to see which lesions have been treated

Bittering agent to mitigate oral ingestion by children

63

---

---

---

---

---

---

---

---

**MYTH:**

“oral antifungals are more dangerous than nail fungus”  
 “and require labs”



64

---

---

---

---

---

---

---

---



**TRUTH:**

- Pulsed dose terbinafine has a high cure rate and extremely low toxicity<sup>1,2,3</sup>
- Onychomycosis significantly increases risks of cellulitis, gangrene, and sepsis<sup>4</sup>

<sup>1</sup>Flawski A, Tavakkoli. Safety and tolerability of oral antifungal agents in the treatment of fungal nail disease: a proven reality. Ther Clin Risk Manag. 2005 Dec; 1(4): 229-306.  
<sup>2</sup>Darkes M, Scott L, Gao M. Terbinafine: a review of its use in onychomycosis in adults. Am J Clin Dermatol. 2002;4(1):33-35.  
<sup>3</sup>Indian J Dermatol Venereol Leprol. Jul-Aug 2005;81(4):303-9. Comparative efficacy of continuous and pulsed dose terbinafine regimens in toenail dermatophytosis: A randomized double-blind trial.  
<sup>4</sup>Dermatology. 2014;229(4):301-7. Chronic dermatomycosis of the feet as risk factors for acute bacterial cellulitis of the leg: a case-control study.

65

---

---

---

---

---

---

---

---



**TRUTH:**

- Data support a regimen of terbinafine 250mg: one a day for 7 days, repeat every 1-3 months for 1-2 years<sup>1,2</sup>.
- Alternately one may prescribe fluconazole 400mg once a week for 18 months, but there are drug interactions to consider.

<sup>1</sup> Indian J Dermatol Venereol Leprol. Jul-Aug 2015;81(4):363-9. Comparative efficacy of continuous and pulsed dose terbinafine regimens in toenail dermatophytosis: A randomized double-blind trial.  
<sup>2</sup> Sprenger, A. B., Purim, K. S. M., Sprenger, F., & Queiroz-Telles, F. (2019). A week of oral terbinafine pulse regimen every three months to treat all dermatophyte onychomycosis. Journal of Fungi, 5(3), 82. <https://doi.org/10.3390/jcf503082>

66

---

---

---

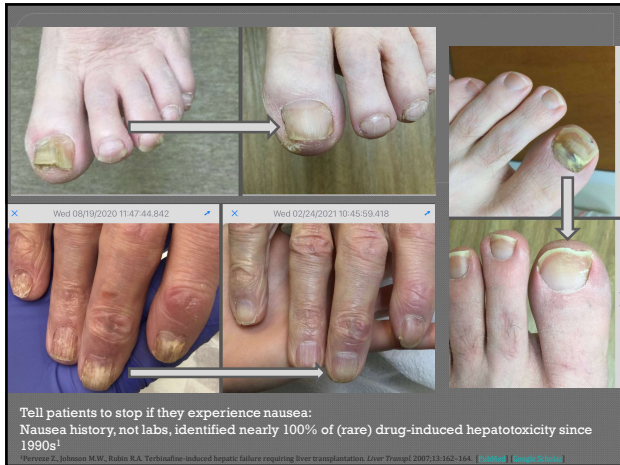---

---

---

---

---



67

---

---

---

---

---

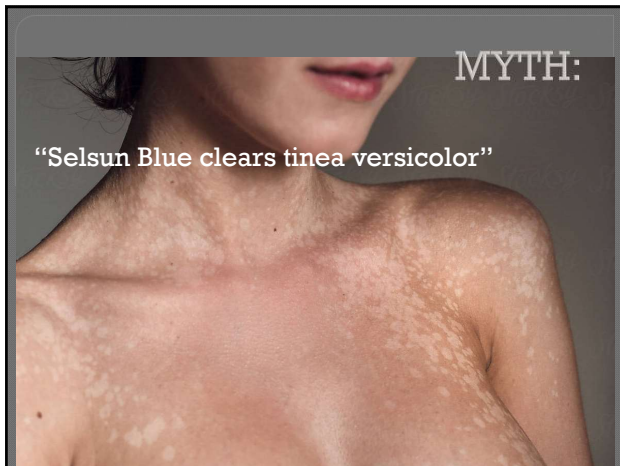
---

---

---

---

---



68

---

---

---

---

---

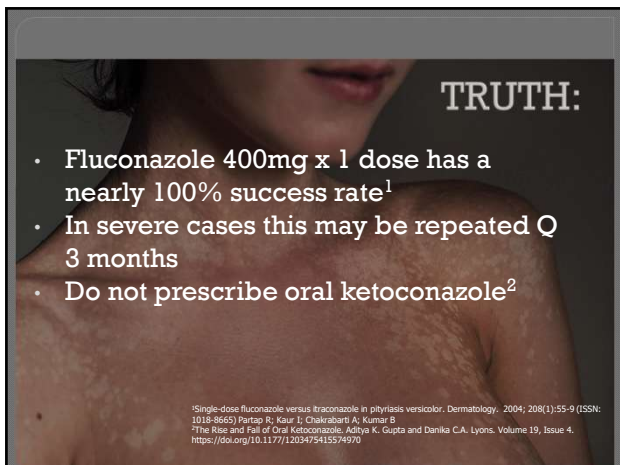
---

---

---

---

---



69

---

---

---

---

---

---

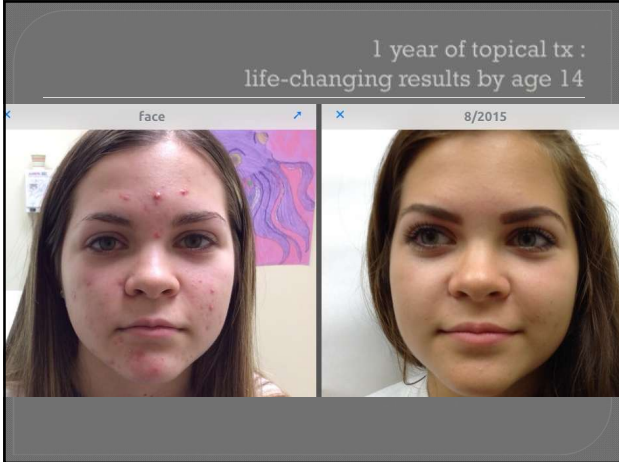---

---

---

---





73

---

---

---

---

---

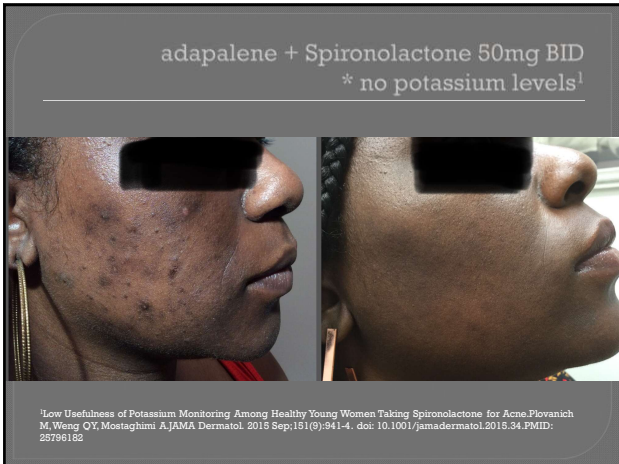---

---

---

---

---



74

---

---

---

---

---

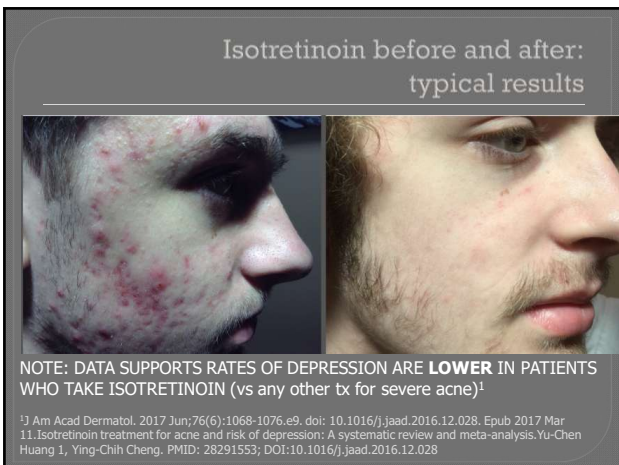---

---

---

---

---



75

---

---

---

---

---

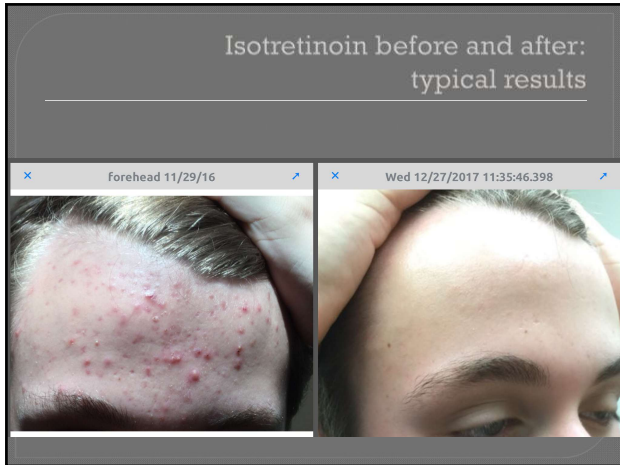
---

---

---

---

---



76

---

---

---

---

---

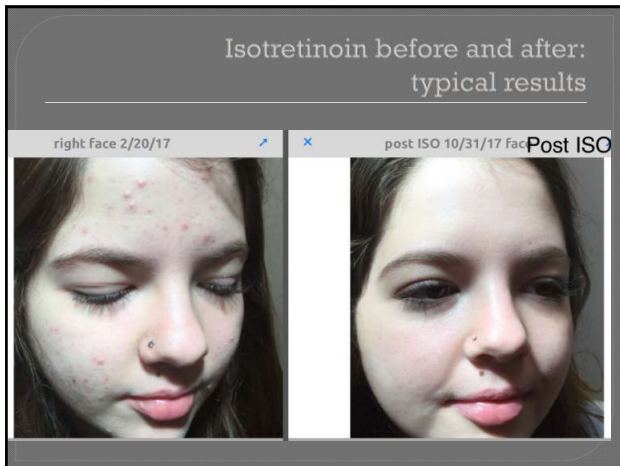
---

---

---

---

---



77

---

---

---

---

---

---

---

---

---

---



78

---

---

---

---

---

---


---

---

---

---

Lice (pediculosis)



- Head lice : mostly school-aged white children (lice prefer dry straight hair)
- Feed on human blood after piercing the skin and injecting saliva → kids only start itching after allergy develops to louse saliva, so diagnosis often delayed months
- Lice die of starvation within 3 days off host, eggs die within 14 days off host

79

---

---

---

---

---


---

---

---

TOPICAL AGENTS FOR HEAD AND PUBIC LICE

OTC



- Pyrethrin shampoos /rinses and spray for surfaces: ineffective due to widespread resistance: Do not recommend
- Various dry-on-the-scalp home remedies (cetaphil, mayonnaise, etc.) to suffocate lice : uncertain effect
- Nit-picking services: expensive but helpful for some

*Lice Bearer*

Call for Help Now! (843) 323-5366  
573 Belle Station Boulevard  
Mt. Pleasant, SC 29464

80

---

---

---

---

---

---

---

---

TOPICAL AGENTS FOR HEAD AND PUBIC LICE

RX: BY PRESCRIPTION



- Permethrin : ineffective due to widespread resistance
- Lindane : NEVER Rx. It can cause seizures
- Topical malathion(Ovide) & ivermectin (Sklice) : single-dose of 10 minutes, and no nit-combing, but resistance reported
- Topical Benzyl Alcohol : resistance reported; not ovicidal; flammable
- Spinosad (Natroba)
  - Extremely low toxicity
  - Very high efficacy
  - Over \$100 if no insurance
  - Only takes 10 minutes, and no need to comb out nits!
  - This is a miracle drug. Start here.



81

---

---

---

---

---

---

---

---

**FYI Spinosad can also be found in common inexpensive garden supply goods. Of course, use on children is off-label so I can't formally recommend this:**

**\$100-\$200 for 4 oz.**

**\$14.99 for 16oz.**

82

---

---

---

---

---

---

---

---

---

---

---

---

### What about RED LIGHT Therapy?

- ⊗ Evidence from high-quality placebo-controlled RCTs supports only modest benefits, such as reduced wrinkles and increased collagen
- ⊗ PBM requires ongoing application for sustained results
- ⊗ Best evidence is for growing increase hair (like the iRestore or Capillus evices)

REFERENCES:  
AMERICAN ACADEMY OF DERMATOLOGY. (2024, SEPTEMBER 12). "IS RED LIGHT THERAPY WORTH IT FOR YOUR SKIN?" [HTTPS://WWW.AAD.ORG/PUBLIC/COSMETIC/SAFETY/RED-LIGHT-THERAPY](https://www.aad.org/public/cosmetic/safety/red-light-therapy)  
JAGDEO, J., NGUYEN, J. K., HO, D., WANG, E. B., AUSTIN, E., MAMALIS, A., MAUR, R., KRNEVA, E., SCHULMAN, J. M., LI, C. S., HWANG, S. T., WUN, T., MAVERAKIS, E., & ISSEROFF, R. R. (2018). LIGHT-EMITTING DIODES IN DERMATOLOGY: A SYSTEMATIC REVIEW OF RANDOMIZED CONTROLLED TRIALS. "LASERS IN SURGERY AND MEDICINE, 50"(6), 611-626. [HTTPS://DOI.ORG/10.1002/LSM.22785](https://doi.org/10.1002/lsm.22785)

83

---

---

---

---

---

---

---

---

---

---

---

---

### Anything work for hair loss ?

**MINOXIDIL FOR THE WIN!**  
**ORAL AND TOPICAL OPTIONS ARE EFFECTIVE FOR 90% OF PATIENTS:**  
 WOMEN: ½ OF 2.5MG (1.25 MG)  
 MEN: 2.5MG BID (5 MG)  
 TOPICAL: 5% SOLUTION QHS

**ORAL MINOXIDIL 5mg RESULTS**

**Before After**

84

---

---

---

---

---

---

---

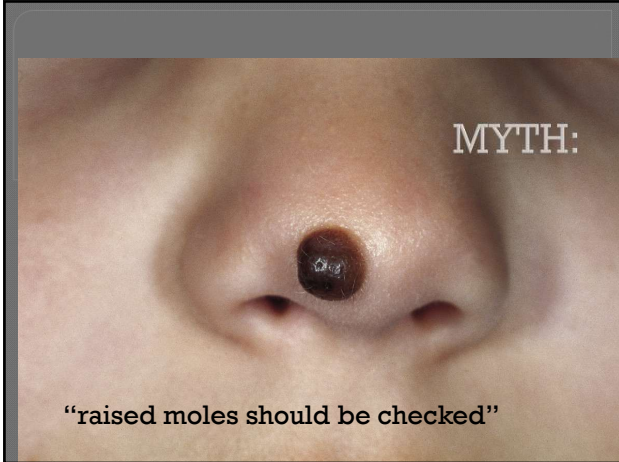
---

---

---

---

---



85

---

---

---

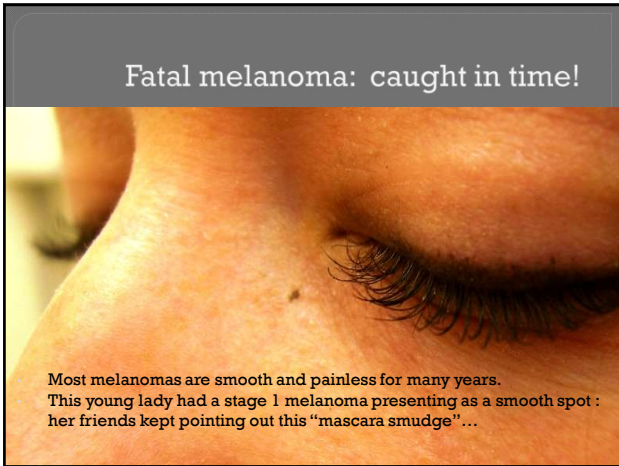
---

---

---

---

---



86

---

---

---

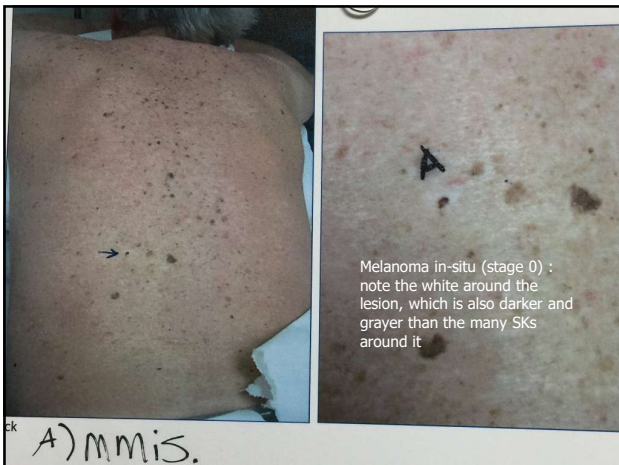---

---

---

---

---



87

---

---

---

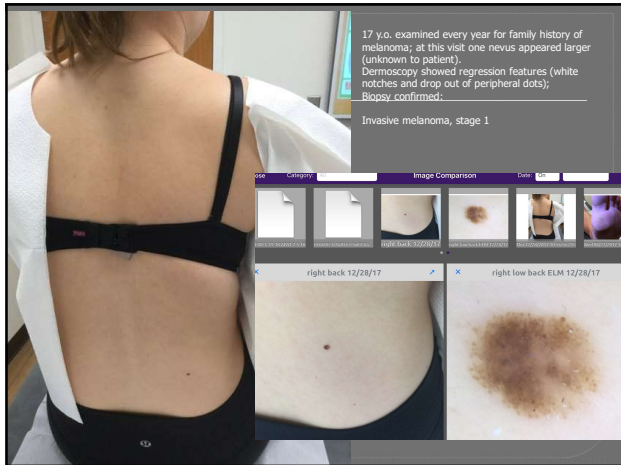
---

---

---

---

---



88

---

---

---

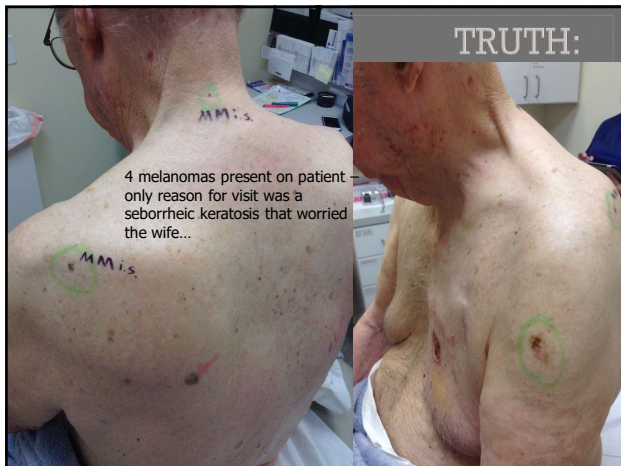---

---

---

---

---



89

---

---

---

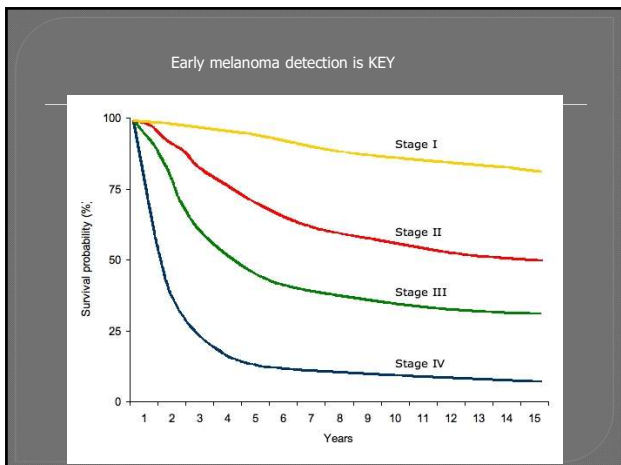
---

---

---

---

---



90

---

---

---

---

---

---

---

---

 <p>1</p>	<p><b>NORMAL MOLE</b> A mole is a small brown spot or growth that appears in the first few decades of life. It can be flat or raised and generally is round.</p>	 <p>4</p>	<p><b>BASAL CELL</b> This is the most common skin cancer. This nonlethal blemish can be a shiny bump, a pink growth, a scar-like area or an open sore that doesn't heal easily.</p>
 <p>5</p>	<p><b>SQUAMOUS CELL</b> Persistent bleeding is common with this rarely deadly cancer. Warts, scaly patches, open sores and rapidly growing bumps are telltale signs.</p>	 <p>6</p>	<p><b>MELANOMA</b> This deadly cancer is usually larger than a pencil's eraser, multicolored and changes size and shape. Also look for asymmetry and uneven borders.</p>

91

---

---

---






---

---

---

---

---

<p><b>A</b></p>	<p><b>ASYMMETRY</b> ONE HALF OF A MOLE DOES NOT MATCH THE OTHER.</p>	
<p><b>B</b></p>	<p><b>BORDER</b> THE EDGES ARE IRREGULAR, RAGGED, NOTCHED, OR BLURRED. NORMAL MOLES ARE ROUND OR OVAL.</p>	
<p><b>C</b></p>	<p><b>COLOR</b> THE MOLE IS NOT EVENLY COLORED. IT MAY INCLUDE SHADES OF BROWN OR BLACK, OR PATCHES OF PINK, RED, WHITE OR BLUE.</p>	
<p><b>D</b></p>	<p><b>DIAMETER</b> THE SPOT IS LARGER THAN 6 MILLIMETERS ACROSS</p>	 <p>LESS THAN .25 IN      GREATER THAN .25 IN</p>
<p><b>E</b></p>	<p><b>EVOLVING</b> THE MOLE IS CHANGING IN SIZE, SHAPE, OR COLOR.</p>	

92

---

---

---

---


---

---

---

---

Melanoma - clinical



A  
B  
C  
D  
E

93

---

---

---

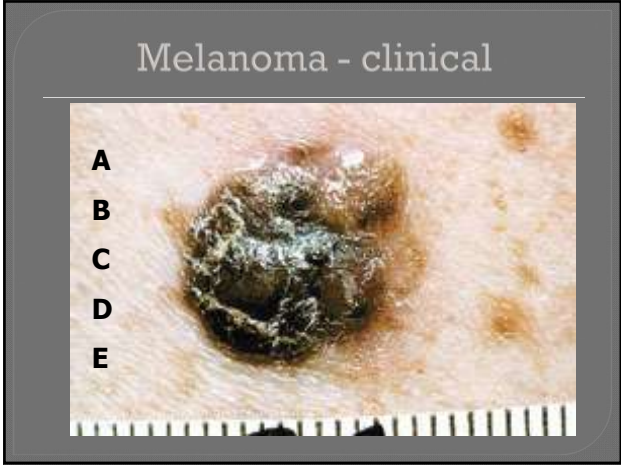
---

---

---

---

---



94

---

---

---

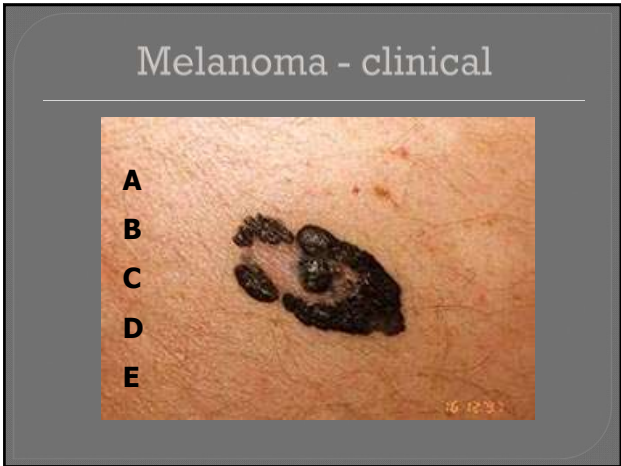---

---

---

---

---



95

---

---

---

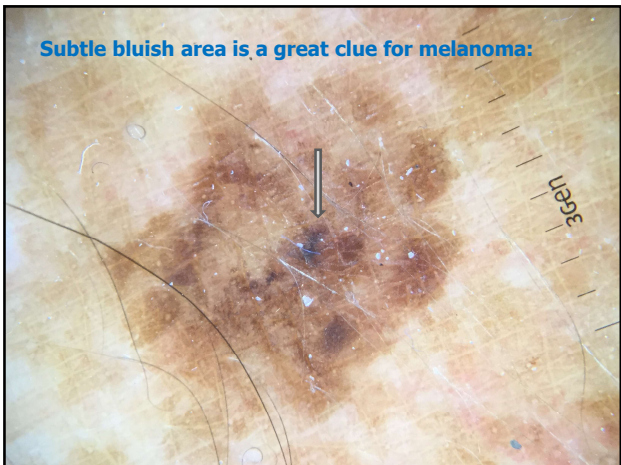
---

---

---

---

---



96

---

---

---

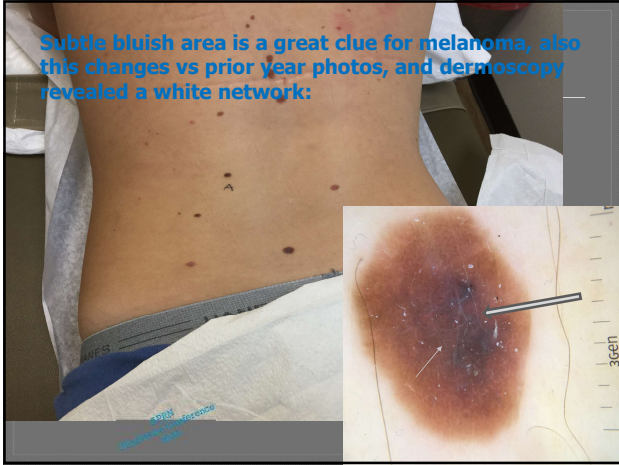
---

---

---

---

---



97

---

---

---

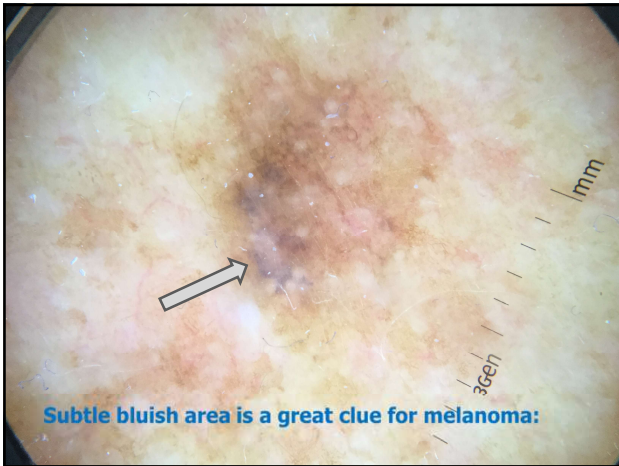
---

---

---

---

---



98

---

---

---

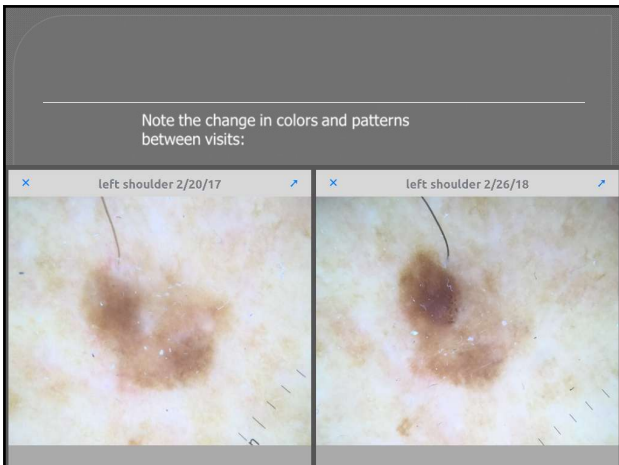
---

---

---

---

---



99

---

---

---

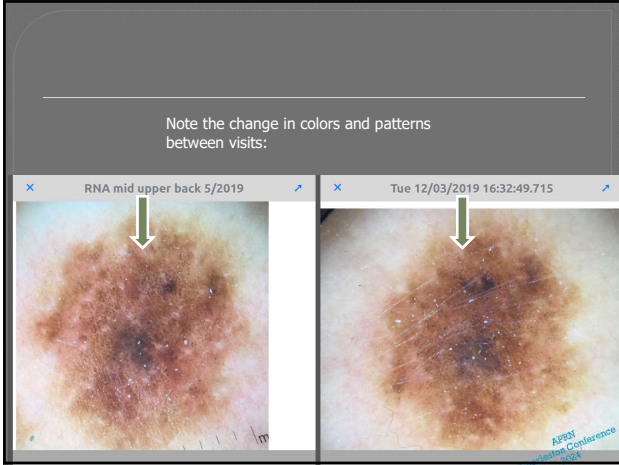
---

---

---

---

---



100

---

---

---

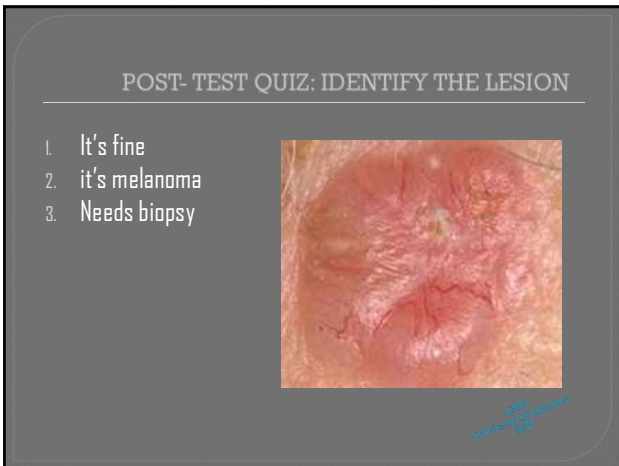
---

---

---

---

---



101

---

---

---

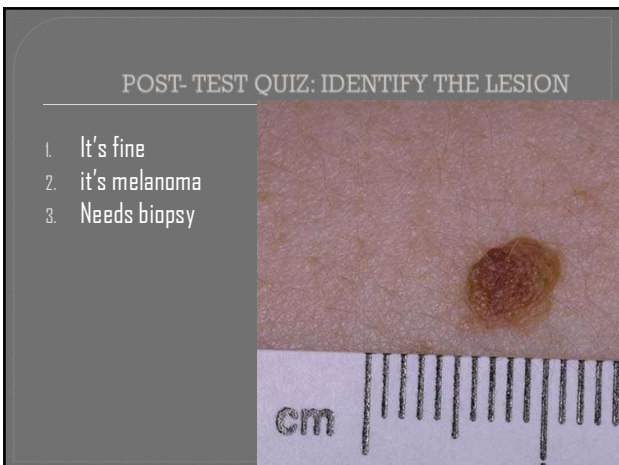---

---

---

---

---



102

---

---

---

---

---


---

---

---

POST- TEST QUIZ: IDENTIFY THE LESION

1. It's fine
2. it's melanoma
3. Needs biopsy



103

---

---

---

---

---


---

---

---

POST- TEST QUIZ: IDENTIFY THE LESION

1. It's fine
2. it's melanoma
3. Needs biopsy



104

---

---

---

---

---


---

---

---

POST- TEST QUIZ: IDENTIFY THE LESION

1. It's fine
2. it's melanoma
3. Needs biopsy



105

---

---

---

---

---


---

---

---

POST- TEST QUIZ: IDENTIFY THE LESION

1. It's fine
2. it's melanoma
3. Needs biopsy



106

---

---

---

---

---

---

---

---

POST- TEST QUIZ: IDENTIFY THE LESION

1. It's fine
2. it's melanoma
3. Needs biopsy



107

---

---

---

---

---

---

---

---

POST- TEST QUIZ: IDENTIFY THE LESION

1. It's fine
2. it's melanoma
3. Needs biopsy



108

---

---

---

---

---


---

---

---

POST- TEST QUIZ: IDENTIFY THE LESION

1. It's fine
2. it's melanoma
3. Needs biopsy



109

---

---

---

---

---


---

---

---

POST- TEST QUIZ: IDENTIFY THE LESION

1. It's fine
2. it's melanoma
3. Needs biopsy



110

---

---

---

---

---

---

---

---

POST- TEST QUIZ: IDENTIFY THE LESION

1. It's fine
2. it's melanoma
3. Needs biopsy



111

---

---

---

---

---


---

---

---

Thank You

- ★ MICHAEL OVERCASH PA  
youtube.com/@MichaelOvercash
- ★ OFFICE LOCATION  
Trident Dermatology  
<https://www.tridentderm.com/>
- ★ EMAIL  
MichaelOvercash@gmail.com



112

---

---

---

---

---

---

---


---

QUESTIONS ?

If you are interested in shadowing, half-day shadow spots are available. Contact the 2026 student representative:

Cathy Davis : DaviCath@musc.edu

Davis, Catherine <davicath@musc.edu>



113

---

---

---

---

---

---

---

---

Next: a gift for you! Flash cards!  
Print and cut then fold...

114

---

---

---

---

---

---

---

---



## Secret bonus material!

- You don't need to drink more water; hydration is a gimmick and does nothing for skin
- We have no brown recluses in SC
- Cutting a melanoma does not make it spread

• A pill for aggressive Basal Cell Carcinoma: ERIVEDGE

• No need to buy expensive UPF clothing: NO! Kenneth Bielinski, MD, Nolan Bielinski, BS, UV Radiation Transmittance: Regular Clothing Versus Sun-Protective Clothing. *Cutis*. 2014 September;94(3):135-138.

• Oral sunscreen: HelioCare ... does it work: YES! Ei-Haj N, Goldstein N. Sun protection in a pill: the photoprotective properties of Polypodium leucotomum extract. *Int J Dermatol*. 2014 Jul; 53(7):1220-1221.

• Does SPF over 30 make a difference? YES! Choi O, Apas Y, Gu-Yang H. A broad spectrum high-SPF photostable sunscreen with a high UVA-PF can protect against cellular damage at high UV exposure doses. *Photodermatol Photoimmunol Photomed*. 2014 Aug;30(4):202-9.

• A shot that makes you tan: MELANOTAN II BMJ Case Rep. 2016 Feb;2016(2):e227544. doi: 10.1136/bcr-2016-227544. Melanotan-induced pruritus: a hard-earned tan. *Braz J Dermatol*. 2015; 59(1):103-104.

---



---



---



---



---



---



---